

CORRESPONDENCE

Open Access



# Comment on: Proposal for a new diagnostic classification of photodistributed Stevens–Johnson syndrome and toxic epidermal necrolysis

Bukiwe N. Thwala<sup>1,4†</sup>, Nadine Teixeira<sup>1,4†</sup>, Eddy Zitha<sup>2</sup>, Aneliswa Mpungose<sup>1,4</sup>, Thuraya Isaacs<sup>2,4</sup>, Jonathan G. Peter<sup>1,3,4</sup> and Rannakoe J. Lehloeny<sup>2,4\*</sup>

## Abstract

Stevens–Johnson syndrome (SJS), toxic epidermal necrolysis (TEN), and SJS/TEN overlap (SJS/TEN), collectively referred to SJS/TEN, form a spectrum of severe life-threatening adverse drug reactions whose pathomechanism is not fully understood. The article "Photodistributed Stevens–Johnson Syndrome and Toxic Epidermal Necrolysis: A Systematic Review and Proposal for a New Diagnostic Classification" by McKinley et. al., discusses a distinct distribution of epidermal necrosis in SJS/TEN, attributable to preceding exposure to ultraviolet radiation (UVR), and relative sparing of photo-protected areas. After reviewing numerous cases within the Immune-mediated Adverse drug Reactions in African HIV endemic setting Register and Biorepository (IMARI-SA) at the University of Cape Town with a similar clinical pattern as those published by McKinley et. al., we propose that the relative sparing of some areas giving an impression of photo-distribution is due to localised increase in skin pressure that reduces the blood supply in that area below a critical threshold. A dip in blood supply below this critical threshold quantitatively limited T lymphocytes and cytokines that drive SJS/TEN to reach and damage the skin.

<sup>†</sup>Bukiwe N. Thwala and Nadine Teixeira contributed equally to this work.

\*Correspondence:

Rannakoe J. Lehloeny  
[rannakoe.lehloeny@uct.ac.za](mailto:rannakoe.lehloeny@uct.ac.za)

<sup>1</sup> Division of Allergy and Clinical Immunology, Department of Medicine, Groote Schuur Hospital and University of Cape Town, Cape Town, South Africa

<sup>2</sup> Division of Dermatology, Department of Medicine, Groote Schuur Hospital and University of Cape Town, Cape Town, South Africa

<sup>3</sup> Allergy and Immunology Unit, University of Cape Town Lung Institute, Cape Town, South Africa

<sup>4</sup> Combined Drug Allergy Clinic and Groote Schuur Hospital, Cape Town, South Africa

## The Editor,

We read with interest the article by McKinley, Allen, and Michels titled "Photodistributed Stevens–Johnson Syndrome and Toxic Epidermal Necrolysis: A Systematic Review and Proposal for a New Diagnostic Classification". The authors reviewed a total of 13 SJS/TEN cases that reported preceding and temporally related ultraviolet radiation (UVR) exposure to support their hypothesis that UVR was responsible for the distinct distribution of epidermal necrosis in these cases [1]. We commend the authors for their thorough and detailed review that makes a valuable contribution to the SJS/TEN literature while stimulating a discussion. Nonetheless, we would



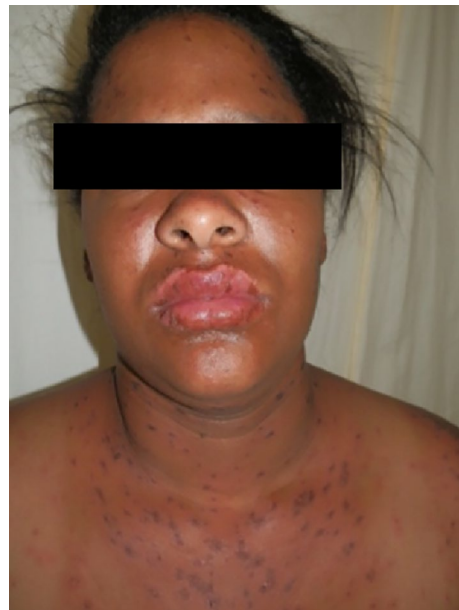© The Author(s) 2024. **Open Access** This article is licensed under a Creative Commons Attribution 4.0 International License, which permits use, sharing, adaptation, distribution and reproduction in any medium or format, as long as you give appropriate credit to the original author(s) and the source, provide a link to the Creative Commons licence, and indicate if changes were made. The images or other third party material in this article are included in the article's Creative Commons licence, unless indicated otherwise in a credit line to the material. If material is not included in the article's Creative Commons licence and your intended use is not permitted by statutory regulation or exceeds the permitted use, you will need to obtain permission directly from the copyright holder. To view a copy of this licence, visit <http://creativecommons.org/licenses/by/4.0/>. The Creative Commons Public Domain Dedication waiver (<http://creativecommons.org/publicdomain/zero/1.0/>) applies to the data made available in this article, unless otherwise stated in a credit line to the data.

like to highlight some limitations of the article, which, if addressed, would strengthen its conclusions. Additionally, we offer an alternative explanation for the clinical pattern described in some of the reported cases.

In a study proposing a new subtype of SJS/TEN and its classification, the onus lies with the authors to as much as possible to only include true cases. Use of these validation scores to include only definite (possibly probable) cases would ensure that they meet the generally acceptable case definition of SJS/TEN. This would allow the authors to describe the differences more precisely with SJS/TEN as generally accepted. The RegiSCAR and J-SCAR validation criteria are the two most widely used validation scores [2, 3]. Closer scrutiny of each case and how SJS/TEN was defined, rather than basing inclusion on the authors' opinion formally designating the case as SJS/TEN, would further strengthen the article. Similarly, it is our view that the inclusion of five cases with a final ALDEN score of 2–3 (possible) falls short of internationally acceptable standards. Although this does not impact case definition in the current article, it has a bearing on the case inclusion criteria and ascribing drug causality in the proposed future studies to validate the author's findings and classification.

Photo-induced reactions generally start in photoexposed areas. In the case of immune-mediated forms, photoallergic reactions are a prime example, and the rash subsequently progresses to photoprotected areas [4]. McKinley et al. specifically addressed this by excluding cases with a sharp cutoff typical of phototoxic reactions. However, they described SJS/TEN lesions beyond sun-exposed areas at first presentation, including mucosal and palmoplantar involvement in 12/12 and 5/6 cases, respectively [1]. Detailing the sequence in which the photoexposed and protected areas were initially affected would be helpful, otherwise this brings to question the veracity of attributing causality to UVR as an explanation for this clinical pattern.

We propose that some of the areas that were relatively spared represent areas of increased local pressure on the skin rather than photo-induced or aggravated pattern. We have often seen the pattern illustrated in the images published by McKinley et al. in our SJS/TEN patients. We usually interpreted these as areas of relative sparing due to pressure from clothes and/or from prolonged anatomical positions that patients assume during the early stages of an evolving SJS/TEN. We reviewed SJS/TEN cases in our Immune Mediated Adverse Reactions in Africa (IMARI-Africa) database,

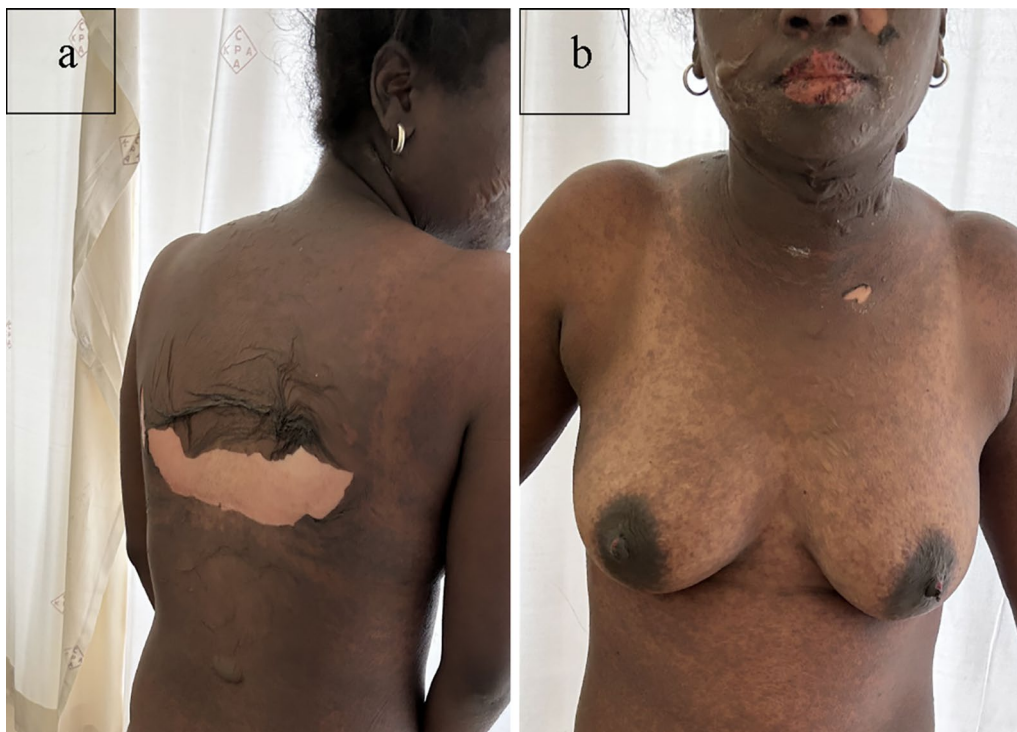


**Fig. 1** Rash distribution similar to that published by McKinley et al. Relative sparing of areas covered by a brassiere

a multinational, multicentre prospective registry, and biorepository of severe adverse drug reactions [5]. We found numerous cases with a clinical pattern similar to the clinical images published in the article, as illustrated in Figs. 1 and 2. IMARI-Africa is approved by the University of Cape Town Human Research Ethics Committee, and the patients shown in these pictures gave written consent for publication of their non-identifying images in a scientific journal.

We hypothesize that areas of sustained pressure on the skin reduce the blood supply below a critical threshold that prevents pathogenic T lymphocytes and cytokines from damaging the skin. Once the pressure is relieved, the disease progresses to involve these areas dependent on the circulating quantities of these cells and cytokines at that time point. We further hypothesize that the critical threshold and duration of vascular impairment to the skin's blood supply is well above that required for skin necrosis under normal circumstances.

We believe that our insights offer another perspective on the clinical patterns observed by McKinley et al. in SJS/TEN. We hope our contribution stimulates further dialogue and encourages continued exploration into the intricate mechanisms underlying this potentially life-threatening reaction. Furthermore, we aim to systematically review all our cases in the near future to determine the veracity of our hypothesis versus that of McKinley et al.



**Fig. 2** Rash distribution similar to that published by McKinley et al. Relative sparing of areas covered by a brassiere

#### Author contributions

BN and NT equally contributed to writing the main manuscript. AM reviewed the images and EZ reviewed the first draft. T.I and JP reviewed the manuscript and were involved in the final draft of the manuscript. RL conceptualised and supervised the writing of the manuscript. All authors were involved in the review and approval of the final draft.

#### Funding

The IMARI-Africa project is part of the EDCTP2 programme supported by the European Union (Grant number TMA2017SF-1981). The IMARI-SA Registry and Biorepository is supported by the National Institute Of Allergy And Infectious Diseases of the National Institutes of Health under Award Number R01AI152183. JP is supported by the South African Medical Research Council, the National Research Foundation and receives funding from NIH (K43TW011178) and NIH Fogarty career development award (K43TW011178-04). RL is supported by the South African Medical Research Council and non-rated researcher support from the South African National Research Foundation. Funders played no role in any aspect of this Review.

#### Availability of data and materials

Not applicable.

#### Declarations

##### Ethics approval and consent to participate

The IMARI-SA study was approved by the University of Cape Town Faculty of Health Sciences Human Research Ethics Committee (HREC Ref No: R031/2018). The participants provided full written informed consent to participate in this study.

##### Competing interests

The authors declare that they have no known competing financial interests or personal relationships that could have appeared to influence the work reported in this paper.

Received: 19 September 2023 Accepted: 8 January 2024

Published online: 29 January 2024

#### References

- McKinley BJ, Allen ME, Michels N. Photodistributed Stevens-Johnson syndrome and toxic epidermal necrolysis: a systematic review and proposal for a new diagnostic classification. *Eur J Med Res.* 2023;28(1):188.
- Sotozono C, Ueta M, Nakatani E, Kitami A, Watanabe H, Sueki H, et al. Predictive factors associated with acute ocular involvement in Stevens-Johnson syndrome and toxic epidermal necrolysis. *Am J Ophthalmol* 2015;160(2):228-37.e2.
- Roujeau J-C. Epidermal necrolysis (Stevens-Johnson syndrome and toxic epidermal necrolysis): historical considerations. *Dermatol Sin.* 2013;31(4):169-74.
- Hofmann GA, Weber B. Drug-induced photosensitivity: culprit drugs, potential mechanisms and clinical consequences. *J Dtsch Dermatol Ges.* 2021;19(1):19-29.
- IMMune-mediated Adverse drug Reactions In African HIV endemic setting (IMARI-SA study): U.S. National Institutes of Health 2018. <https://www.fic.nih.gov/Grants/Search/Pages/emerging-global-leader-tw011178.aspx>.

#### Publisher's Note

Springer Nature remains neutral with regard to jurisdictional claims in published maps and institutional affiliations.